

Case Report

Periprosthetic fracture of total hip replacement in patients with osteopetrosis: A case presentation and review of literature

Eftychios Papagrigorakis, Athanasios Galanis, Christos Vlachos, Michail Vavourakis, Dimitrios Zachariou, John Vlamis, Spiros Pneumaticos

3rd Department of Orthopaedic Surgery, National & Kapodistrian University of Athens, KAT General Hospital, Athens, Greece

Abstract

Osteopetrosis is a rare inherited bone disease characterized by impaired osteoclast activity. Total joint replacement is often necessary in these patients, as osteoarthritis is an early manifestation of the disease. However, only a few cases of periprosthetic fractures have been reported in the literature. A 73-year-old female patient sustained a periprosthetic fracture of the right femur after a fall from standing height. The patient had undergone a total hip arthroplasty surgery 10 years ago. Intraoperatively both the acetabular cup and the femoral stem were found stable, thus the fracture was treated using plating with locking screws and cables. No postoperative complication was observed and the fracture was completely healed after 6 months. Periprosthetic fracture management poses special difficulties and technical issues in patients with osteopetrosis. Hematologist consultation is an important part of the preoperative preparation, while a careful postoperative follow-up is crucial due to the high rates of postoperative complications. The intraoperative technical challenges in the management of an osteopetrotic bone are many due to the abnormal bone density. Orthopedic surgeons have to engage specific strategies to avoid pitfalls as interventions are technically challenging, leading to prolonged operative time and increased blood loss.

Keywords: Internal fixation, Open reduction, Osteopetrosis, Periprosthetic fracture, Total hip arthroplasty

Introduction

Osteopetrosis (OP), also known as marble disease, is a heterogenous group of inherited bone dysplasias characterized by impaired osteoclastic activity, leading to increased bone density. The disease is generally divided into 3 groups: infantile malignant autosomal recessive, intermediate autosomal and two types of benign autosomal dominant OP (ADO)¹. The most common clinical findings, in the intermediate autosomal group, are increased bone density and frequent fractures from a young age. These patients generally survive till adulthood. Benign autosomal dominant OP is the most common form. It is usually mild and consists of two subtypes. Type 1 (ADO 1) involves thickening of the cranial vault. Type 2 autosomal dominant OP or Albers Schoenberg disease (ADO 2) is characterized by sclerosis of the pelvis, the vertebrae and the base of the skull. These patients have a normal life expectancy.

A common manifestation in ADO 2 is early onset hip and knee osteoarthritis^{2,3}. As there is no definite treatment

for OP, while the osteoarthritis is usually recalcitrant to conservative treatment, total joint arthroplasty is nowadays frequently used in such cases⁴. However, operative treatment bears a high complication risk and is associated with an increased level of technical difficulty. The biggest issues in patients with OP undergoing arthroplasty are iatrogenic fractures during implant placement, obliteration of the femoral medullary canal, an increased risk of osteomyelitis, and postoperative periprosthetic fractures^{3,5}.

The authors have no conflict of interest.

Corresponding author: Michail Vavourakis, Orthopaedic Resident, Chelmou 6, Neo Irakleio, Athens, Greece 14122

E-mail: michail.vavourakis@outlook.com

Edited by: Jagadish Chhetri

Accepted 7 September 2022

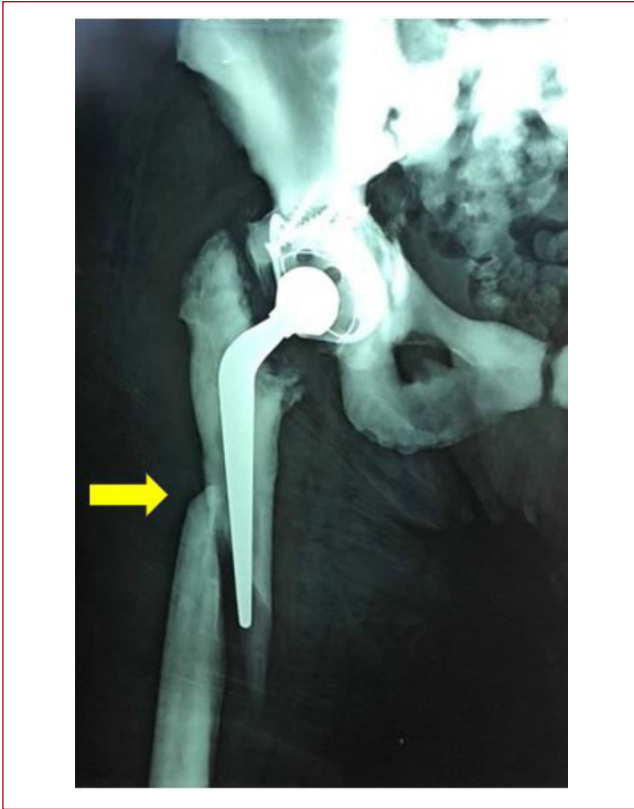


Figure 1. Periprosthetic fracture of the right femur in a patient with medical history of ADO 2.

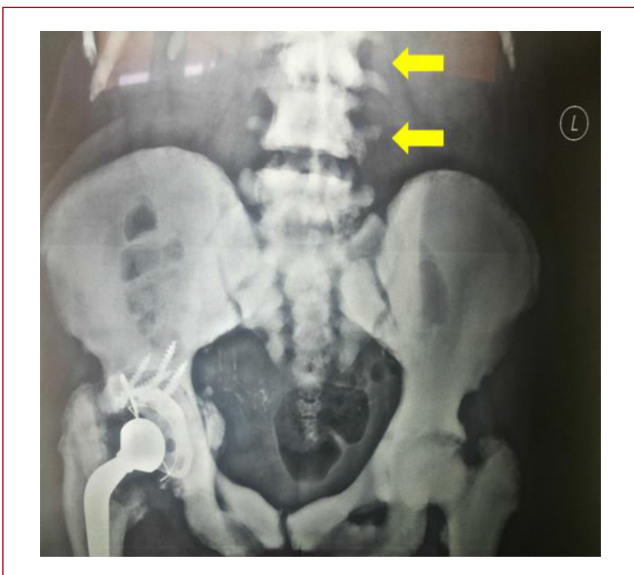


Figure 2. Increased bone density of the pelvic ring and rugger jersey spine presentation (arrows) in a patient with positive history of ADO 2 OP.

We present the case of a 73-year-old woman with autosomal dominant type 2 OP who suffered a periprosthetic fracture of her right femur, which was treated with open reduction and internal fixation (ORIF). There are very few reports among literature on the treatment of periprosthetic fractures in such patients.

The purpose of this report is to highlight the perioperative difficulties regarding the treatment of such a rare case of periprosthetic femoral fracture in a fragile elderly patient with OP and to provide a rationale for the surgical management.

Case Presentation

A 73-year-old female patient presented to the emergency department of our hospital after falling from standing height, complaining of right hip pain, while unable to bear weight. The patient suffered from type 2 benign autosomal dominant OP (ADO 2). She had undergone a total hip replacement surgery 10 years ago, due to degenerative osteoarthritis. The radiological evaluation revealed a periprosthetic fracture of the right femur (Figure 1).

Apart from the fracture, characteristic bone changes were present on the x-rays including high bone density, rugger jersey spine and Erlenmayer flask deformity in the distal femur (Figures 1, 2).

Further evaluation of the fracture site with a computed tomography scan revealed an obliteration of medullary canals of both femurs (Figure 3).

The patient had a history of hypertension and diabetes mellitus 2. She received erythropoietin every 20 days and granulocyte colony stimulating factor twice per week during the last five years due to bone marrow insufficiency attributed to decreased intramedullary space caused by OP. After thorough consultation with the hematologists, the patient received 5 packed red blood cell units (lowest Hb value: 7.6 g/dL) and 3 platelet units (lowest PLT value: 44.000/ μ L) preoperatively.

After the restoration of the hemoglobin and platelet count, the patient was taken to the operating room. Intraoperatively, the fracture was classified as Vancouver B1, as the femoral stem and the acetabular cup were stable. The fracture was reduced with gentle manipulation and fixed with a locking plate (Zimmer, NCB Periprosthetic Femur Plate System), screws and cables (Figure 4). The drilling of the bone was remarkably difficult and time consuming (three to four times above normal). The drill bits were changed frequently and the drilling site was kept under constant saline irrigation to reduce the excessive heat. Any bending forces were avoided as well as the usage of mallet to decrease the risk of any further iatrogenic fracture.

The postoperative course was uncomplicated. However, there was raised alertness due to patient's the bone marrow insufficiency and the possible perioperative stress effect on it. Postoperatively, the patient received 3 units of packed red blood cell, but no platelet transfusion was deemed necessary. Both erythropoietin and

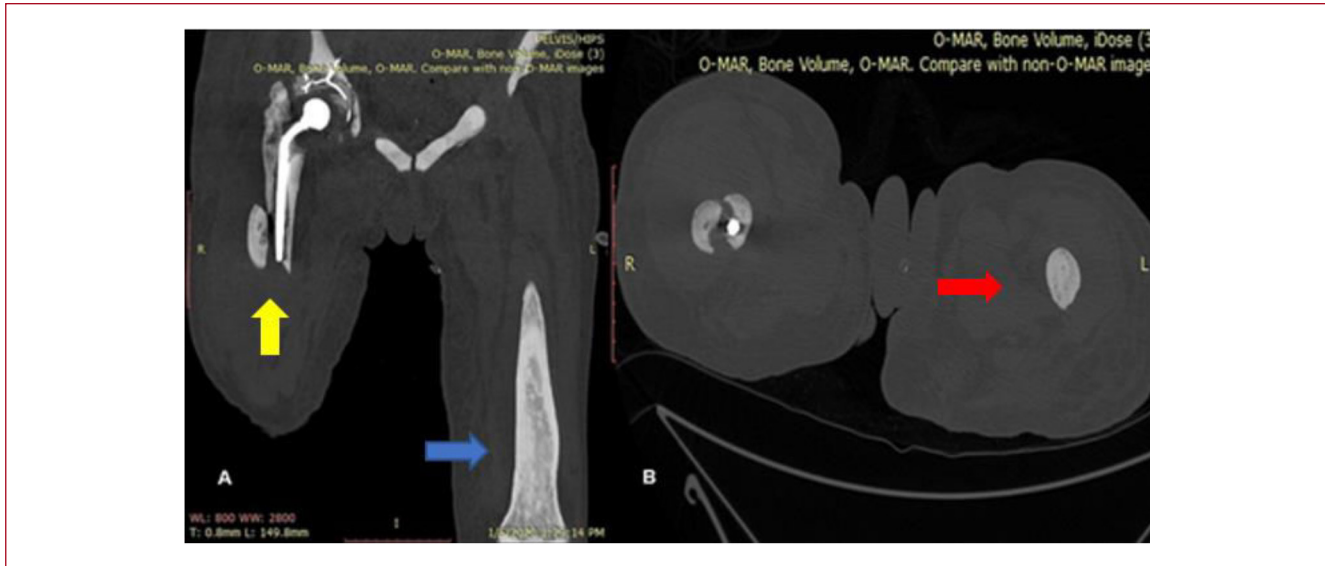


Figure 3. CT scan depicting a periprosthetic fracture of the right femur (yellow arrow), obliterated medullary canals (red arrow) and the characteristic Erlenmeyer flask deformity of the distal femur (blue arrow). A. coronal view, B. axial view.

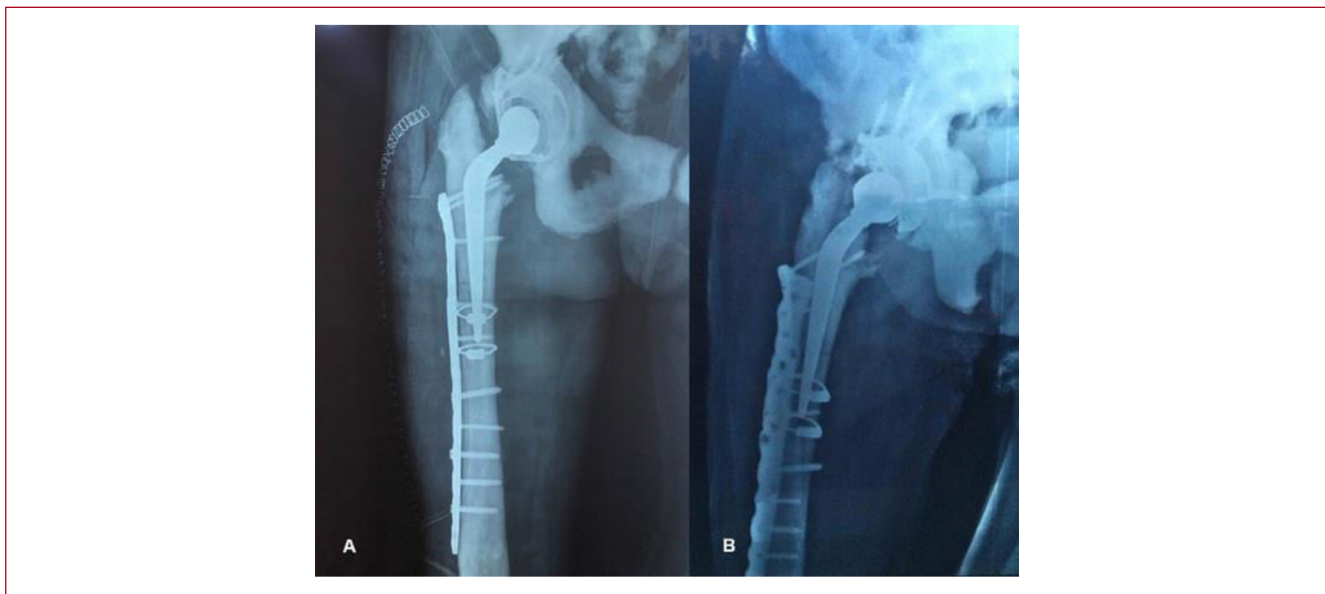


Figure 4. Postoperative X-ray. A. face plane, B. profile plane.

granulocyte colony stimulating factor were administered throughout the pre- and postoperative period according to the hematological advice.

The patient was advised to avoid weight-bearing ambulation through the first 6 weeks postoperatively, partially bear weight from the 6th week, while full weight

bearing was allowed on the 4th month. The fracture was considered healed by the 6th month (Figure 5). On her last visit, two years postoperatively, the patient was ambulatory with the help of a cane and had a Harris hip score of 83,6 out of 100, constantly improving since the operation.

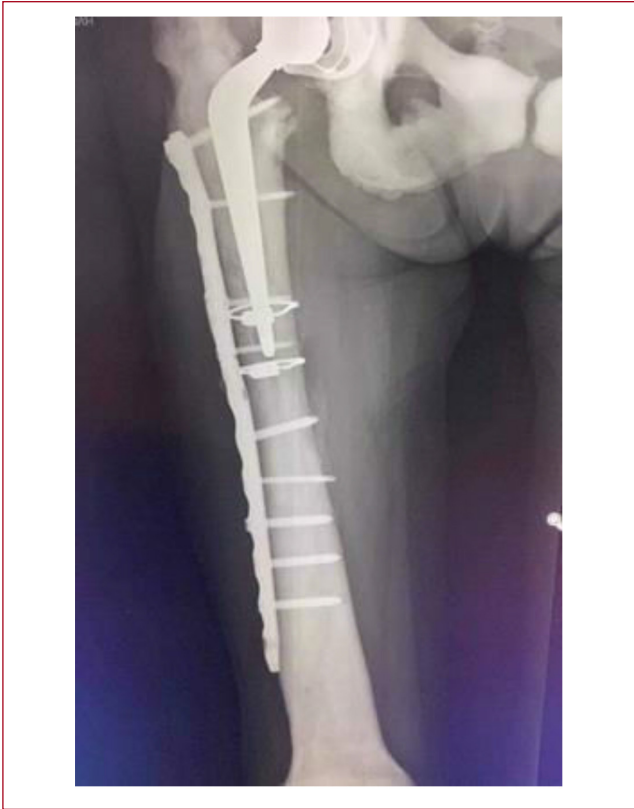

Figure 5. Radiologic evaluation at the six-month follow-up with evident callus formation.

Discussion

Albers Schoenberg disease or the autosomal dominant type 2 OP is the most common form of the disease. Its most common clinical manifestation are fractures of the long bones in approximately 75% of the patients². The exact prevalence of the disease is not known as an estimated 40% of the patients remain asymptomatic⁶. Historically, fractures in OP patients were treated conservatively with satisfactory results, although the rate of healing was frequently noted to be prolonged, as osteopetrotic fractures do heal but remodeling does not seem to occur⁷. Current literature supports non-operative treatment only for diaphyseal long bone fractures of upper and lower limb, especially in children. Conservative management of intertrochanteric and subtrochanteric fractures, on the contrary, can lead to delayed healing and progressive coxa vara deformity. Thus, these fractures are preferentially treated operatively^{8,9}. The reported complication rates in the largest series among literature for peritrochanteric fractures in osteopetrotic patients are 12% for non-union, 12% for infection, 29% for hardware failure and 14-44% for periprosthetic fracture^{5,10,11}. However, as Ding et al highlight in their report,

after 2005, with the accumulation of clinical and operative experience in the treatment of osteopetrosis-associated fractures, reports of complications after surgical treatment decreased significantly. They report that the complication rate decreased from 54.5% to 21% after 2005¹².

Early onset hip and knee osteoarthritis is closely related to patients with ADO 2. As in our case, it is a common orthopaedic manifestation of the disease, arising in mid-adult life. Its treatment is nowadays mainly operative and total arthroplasty is a viable solution for these patients who have a full-life expectancy^{3-5,13-15}. Unfortunately, total arthroplasty in the setting of OP is a challenging procedure associated with an increased level of intraoperative technical difficulty and a high risk of complications^{5,16}. Most reports emphasize on the technical difficulties, especially on the femoral component, which result in prolonged operative time and increased blood loss¹⁷. The most common problems include iatrogenic fractures during press fit implant insertion, the penetration of the femoral cortex due to the obliterated femoral medullary canal, and an increased risk for osteomyelitis^{3,5}. To overcome these difficulties, the use of high-speed burrs, metal cutting drill bits, and power drills to recreate a medullary canal under fluoroscopic guidance, or even computer assisted navigation, have been reported^{4,13,18,19}. Bending and torsional forces, and the use of a mallet is discouraged⁶. The use of small sized femoral components is recommended and custom-made femoral stems have been used in some cases^{14,18}. The optimal strategy for total hip arthroplasty (THA) in cases of OP has yet to be determined, as there is lack of evidence on long-term results¹³.

Periprosthetic femoral fracture remains a severe postoperative complication following THA in patients with OP^{3,5,11,15}. The reported rate for postoperative periprosthetic fracture ranges from 14%¹¹ to 44%⁵. A total of six cases of postoperative periprosthetic fractures after THA in patients with ADO 2 were identified among literature (Table 1). The treatment options of periprosthetic femoral fractures in patients with OP vary. These include femoral stem revision, internal fixation with or without bone grafting and conservative treatment. In one case, after multiple atraumatic fractures in an 18-year period, the most recent fracture resulted in femoral stem instability and a resection arthroplasty was performed. When the femoral stem is found stable intraoperatively (classified as Vancouver B1), as in our patient, ORIF with or without bone graft, is the treatment of choice. Conservative treatment is also a good option in selected patients, as Zhang et al.¹⁵ pointed out, with their case showing a good functional result within a 10-year follow-up.

An important observation by Siljander et al.⁵ is that all postoperative periprosthetic femoral fractures in their series occurred in patients with intramedullary diameter less than 5 mm, at a level 10 cm distal to the lesser trochanter. Femoral fractures appear to be associated with a smaller

Authors	Age	Sex	Limb affected	Femoral stem (cemented/uncemented)	Type of fracture (Vancouver classification)	Cause	Years post THA	Treatment	OP type	Follow-up post THA
Zhang et al. ¹⁵	44	M	L	Uncemented	B2	Minor fall	4w	Conservative	ADO II	10
Benum et al. ¹⁸	32	F	R	Uncemented	B1	Minor fall	4y	ORIF + allogenic bone graft	ADO II	7
Siljander et al. ⁵	24	F	R	Cemented	B1	Atraumatic	5y	ORIF	ADO II	10.1
Siljander et al. ⁵	34	F	L	Cemented	B1	Atraumatic	1y	ORIF	ADO II	1.2
Siljander et al. ⁵	55	F	R	Uncemented	B2	Intraoperative fracture and postoperative fracture displacement with femoral stem subsidence	Weeks	Femoral component cemented revision	ADO II	0.5
Siljander et al. ⁵	47	M	R	Cemented	Multiple fractures in 18 years	Atraumatic	Years	Conservative till resection arthroplasty	ADO II	19.2

THA – total hip arthroplasty. ADO – autosomal dominant osteopetrosis

Table 1. Postoperative periprosthetic fractures in patients with osteopetrosis

intramedullary diameter, possibly due to the inferior biomechanics of the femur when the medullary canal is obliterated. In our case the medullary canal of the femur was also completely obliterated (Figure 3). Another interesting point is that, in most cases, fractures are the result of a minor fall or occur even completely atraumatic. The fractures occurred from 4 weeks to 18 years postoperatively and there seems to be no correlation with the use of a cemented or uncemented stem (Table 1). In conclusion, THA is recognized by most authors as a good option, despite some technical difficulties, and is associated with good 10-year implant survivorship (89%), despite a very high reoperation (58%) and periprosthetic femoral fracture rate (44%)⁵.

Bone marrow failure should be taken under consideration as it may complicate the perioperative care of patients with OP. It occurs in approximately 19% of ADO 2 patients¹. A hematologist consultation may be beneficial in the fragile elderly with OP and bone marrow insufficiency, as in our case, for the evaluation of the bone marrow stimulating drug usage, and both platelet and red blood cell count control. Preoperatively the patients hematological profile should be optimized due to the prolonged surgical time and increased blood loss that is expected⁴. The lack of bone marrow vascularity and impairment of white cell function, on the other hand, can result in reduced resistance to infection, thus increasing the risk for osteomyelitis postoperatively^{6,9}.

In conclusion, THA is considered a good option for OP patients with painful hip osteoarthritis. Postoperative periprosthetic fractures seem to be a common complication, especially in patients with ADO 2, and are usually associated with the obliteration of the femoral medullary canal. The treatment may vary from conservative to revision

arthroplasty. When the femoral stem is stable (classified as Vancouver B1) ORIF is a viable treatment option. The fragile elderly patients should be optimized hematologically before surgery, as orthopaedic interventions are technically challenging, leading to prolonged operative time and increased blood loss.

Consent to participate

The authors have obtained written consent from the patient presented in this work.

Consent for publication

The authors have obtained written consent for the publication of the data presented in this work.

Authors' contributions

Eftychios Papagrigorakis: Study design, Data collection, Data interpretation, Manuscript preparation, Literature research. Athanasios Galanis: Data interpretation, Manuscript preparation. Christos Vlachos: Data collection, Literature research. Michail Vavourakis: Study design, Manuscript preparation, Literature research. Dimitrios Zachariou: Data collection, Data interpretation. John Vlamis: Study design, Data collection, Data interpretation, Supervision. Spiros Pneumaticos: Study design, Data collection, Data interpretation Manuscript preparation, Literature research.

References

1. Waquespack, SG, Hui SL, Dimeglio LA, Econs MJ. Autosomal dominant osteopetrosis: clinical severity and natural history of 94 subjects with a chloride channel 7 gene mutation. *J Clin Endocrinol Metab* 2007;92(3):771-8.

2. Chawla A, Kwek EBK. Fractures in patients with osteopetrosis, insights from a single institution. *Int Orthop* 2019;43(6):1297-1302.
3. Van Hove RP, De Jong T, Nolte PA. Autosomal dominant type I osteopetrosis is related with iatrogenic fractures in arthroplasty. *Clin Orthop Surg* 2014;6(4):484-8.
4. Strickland JP, Berry DJ. Total joint arthroplasty in patients with osteopetrosis: a report of 5 cases and review of the literature. *J Arthroplasty* 2005;20(6):815-20.
5. Siljander MP, Trousdale RT, Perry KI, Mabry TM, Berry DJ, Abdel MP. Total Hip Arthroplasty in Patients With Osteopetrosis. *J Arthroplasty* 2021;36(4):1367-72.
6. Yiğit Ş, Akar MS, Şahin MA. Mid-term outcomes of surgical treatment in fractures in patients with osteopetrosis. *Bone Joint J* 2020;102-b(8):1082-7.
7. De Palma L, Tulli A, Maccauro G, Sabetta SP, Del Torto M. Fracture callus in osteopetrosis. *Clin Orthop Relat Res* 1994;(308):85-9.
8. Bhargava A, Vagela M, Lennox CM. "Challenges in the management of fractures in osteopetrosis"! Review of literature and technical tips learned from long-term management of seven patients. *Injury* 2009;40(11):1167-71.
9. Lim JY, Kim BS, Yoon BH, Chang JS, Park CH, Koo KH. Lessons Learned from Long-Term Management of Hip Fracture in Patients with Osteopetrosis: A Report of Nine Hips in Five Patients. *J Bone Metab* 2019;26(3):201-6.
10. Amit S, Shekhar A, Vivek M, Shekhar S, Biren N. Fixation of Subtrochanteric Fractures in Two Patients with Osteopetrosis Using a Distal Femoral Locking Compression Plate of the Contralateral Side. *Eur J Trauma Emerg Surg* 2010;36(3):263-9.
11. Birmingham P, McHale KA. Case reports: treatment of subtrochanteric and ipsilateral femoral neck fractures in an adult with osteopetrosis. *Clin Orthop Relat Res* 2008;466(8):2002-8.
12. Ding H, Chen H, Lin H, Xu J, Huang Z, Li W, et al. Further understanding on osteopetrotic femoral fractures: a case report and literature review. *BMC Surg* 2021;21(1):117.
13. Hashimoto A, Sonohata M, Kitajima M, Kawano S, Eto S, Mawatari M. Complications of total hip arthroplasty for patients with osteopetrosis: A report of four hips in two patients. *J Orthop Sci* 2022;27(2):500-3.
14. Xie L, Ding F, Jiao J, Kan W, Wang J. Total Hip and Knee arthroplasty in a patient with osteopetrosis: a case report and review of the literature. *BMC Musculoskelet Disord* 2015;16:259.
15. Zhang ZF, Wang D, Wu LD, Dai XS. Case report: A 10 years follow-up of periprosthetic femoral fracture after total hip arthroplasty in osteopetrosis. *Chin J Traumatol* 2017;20(3):173-6.
16. Ashby ME. Total hip arthroplasty in osteopetrosis. A report of two cases. *Clin Orthop Relat Res* 1992;(276):214-21.
17. Shapiro F. Osteopetrosis. Current clinical considerations. *Clin Orthop Relat Res* 1993;(294):34-44.
18. Benum P, Aamodt A, Nordsletten L. Customised femoral stems in osteopetrosis and the development of a guiding system for the preparation of an intramedullary cavity: a report of two cases. *J Bone Joint Surg Br* 2010;92(9):1303-5.
19. Sen RK, Gopinathan NR, Kumar R, Saini UC. Simple reproducible technique in treatment for osteopetrotic fractures. *Musculoskelet Surg* 2013;97(2):117-21.